

## Conjunctivo-Dacryocystorhinostomy with Tube Implantation in Failed External Dacryocystorhinostomy: A Case Report

Ingrid Yuriani,\* Michael Indra Lesmana,\* Hernando O. Cruz Jr \*\*

\* Staf Pengajar Bagian Mata FK Ukrida

\*\* Fatima Medical Center, Ophthalmology Department 120 Mc Arthur Hi-Way, Marulas, Valenzuela City, Manila, Philippines

Address of Correspondence: Email: inge2psnmama@yahoo.com & Email: mil\_0609\_jlm\_syl@yahoo.com

**Abstract:** Conjunctivo-dacryocystorhinostomy (CDCR) with Lester Jones tube implant is one of the treatment options for patient with failed repeated dacryocystorhinostomy (DCR) with implantation of silicon tube. This is the first CDCR case reported in the Philippines, about a 64-year old Filipino female with chronic epiphora on left eye for 7 years with repeated failure to external Dacryocystorhinostomy, and canaliculi obstruction due to repeated lacrimal irrigation using cut-end needle from tuberculine syringe. Examination revealed positive tearing on left eye, flow back from same puncta without discharge, and dacryoscintigraphy using Tc99m revealed non-flowing dye and pooling at inferior fornix consistent with complete obstruction in the level of left canaliculi. Patient underwent Conjunctivo-dacryocystorhinostomy with Lester Jones' tube implantation of the left eye and was relieved from epiphora. Lacrimal irrigation using a cut-end needle from tuberculine syringe is not recommended due to tendency of developing canaliculi fibrosis. A good education towards patient regarding post operative tube care is necessary to reduce surgical failure.

**Keywords:** Lester Jones' tube, external dacryocystorhinostomy, conjunctivo-dacryocystorhinostomy (CDCR), dacryoscintigraphy, lacrimal apparatus irrigation, epiphora

## Konjungtiva-Dakriosistorhinostomi dengan menggunakan tabung Jones pada Dakriosistorhinostomi Eksterna yang Gagal

Ingrid Yuriani,\* Michael Indra Lesmana,\* Hernando O. Cruz Jr \*\*

\*Staf Pengajar Bagian Mata FK Ukrida

\*\*Fatima Medical Center, Ophthalmology Department 120 Mc Arthur Hi-Way, Marulas, Valenzuela City, Manila, Philippines

Address of Correspondence: Email: [inge2psnmama@yahoo.com](mailto:inge2psnmama@yahoo.com) & Email: [mil\\_0609\\_ilm\\_syl@yahoo.com](mailto:mil_0609_ilm_syl@yahoo.com)

**Abstract:** Konjungtiva-Dakriosistorhinostomi dengan menggunakan tabung Jones adalah salah satu tindakan pilihan untuk pasien yang gagal terapi setelah dilakukan dakriosistorhinostomi eksterna berulang. Kasus ini adalah kasus pertama yang dilaporkan di Filipina, seorang wanita 64 tahun datang dengan keluhan kronik epiphora pada mata kirinya sejak 7 tahun sebelum masuk rumah sakit, dengan riwayat operasi dakriosistorhinostomi eksterna yang berulang dan obstruksi dari kanalikulus yang disebabkan oleh irigasi yang berulang dengan menggunakan ujung jarum yang dipatahkan. Pada pemeriksaan didapatkan epiphora yang positif pada mata kiri, aliran balik dari puntum yang sama tanpa disertai kotoran mata, dan pada dakrioskintigrafi dengan menggunakan Tc99m didapatkan kontras yang tidak mengalir dan bendungan pada fornix bawah yang menunjukkan adanya obstruksi yang lengkap pada kanalikulus kiri. Pasien telah dioperasi konjungtiva-dakriosistorhinostomi dengan menggunakan tabung Lester Jones pada mata kiri dan bebas dari keluhan epiphora setelah operasi. Tindakan irigasi dengan menggunakan semprit dan ujung jarum yang dipatahkan tidak direkomendasikan karena adanya kecenderungan menyebabkan fibrosis dari kanalikulus. Penyuluhan perlu diberikan terhadap pasien terhadap perawatan tabung jones untuk mengurangi angka kegagalan operasi.

**Kata kunci:** Tabung Lester Jones, dakriosistorhinostomi eksterna, Konjungtivo-dakriosistorhinostomi (CDCR), dakrioskintigrafi, irigasi saluran lakrimal, epiphora.

### Introduction

Epiphora, which means excessive tearing due to obstruction of the lacrimal drainage, usually in the level of lacrimal sac, might be a chronic, frustrating problem to some patients in developing country because it causes blurring of vision due to pooling of tears, recurrent infections, and people might ask the patient emotional condition due to the tearing. Obstruction in lacrimal drainage can be corrected with dacryocystorhinostomy (DCR), which is a procedure to create a channel connecting the lacrimal sac to the nasal space. In some cases DCR might fail due to stricture of the attempted fistula and tearing recurs. Repeated

DCR is required, but if failure persisted, then an eye surgeon must have another solution for this problem by the means of maintaining the patency of the fistula.

Lacrimal apparatus irrigation after DCR is necessary to check patency of the fistula and to clean the passage from blood clotting. Proper lacrimal apparatus irrigation has to be done using a special gauge-23 irrigating canula. This procedure is done every follow up until six months post-operation.

Conjunctivo-dacryocystorhinostomy (CDCR) is a procedure to create a drainage channel connecting the conjunctival space to the

nasal space bypassing the canaliculi and the lacrimal sac with or without tube implantation. Conjunctivo-dacryocystorhinostomy (CDCR) with tube implantation has a higher success rate than without implantation. It is opted to be done in patients with extensive canalicular obstruction (proximal obstruction, agenesis or atresia of canaliculi or punctum, failed surgery after DCR with canalicular intubation, canaliculi fibrosis, functional epiphora, lacrimal pump failure, e.g. facial palsy and Centurion syndrome).<sup>1-5</sup>

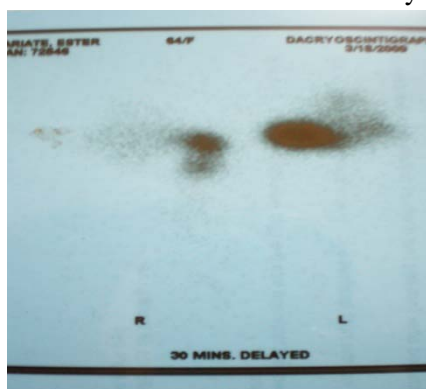
### Case Report

A 64-year old Filipino female was referred to the Ophthalmology Department of Fatima Medical Center with complaint of chronic epiphora on the left eye since seven years prior to consultation. Patient has had her first external DCR with silicon tube implant which was removed after 6 months in 1998. After the procedure she had temporary relieve of symptom for a couple of months but it recurred. In 1999 repeated external DCR with silicon tube implant was done. Both surgeries were done in a government hospital, and patient was routinely checked-up with lacrimal irrigation using a cut-end needle from a tuberculine syringe. Once

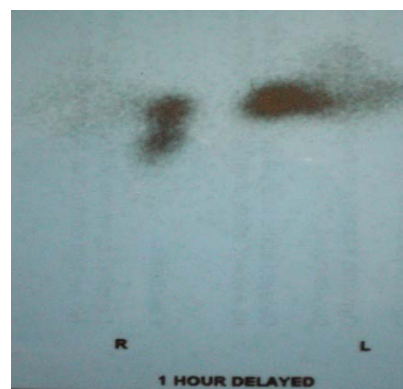
again, temporary relieve occurred but eventually epiphora still relaps.

Due to persistent epiphora patient seek consultation to other hospital and at last referred to our institution. On consultation, patient has visual acuity of 20/40 OU and can be best corrected up to 20/30 OU. There was epiphora on the left eye, with no inflammation, pain, or eye discharge and there is a visible skin scar from previous surgeries at medial canthal area. Upon lacrimal irrigation through lower canaliculi of the left eye, flow back was observed from the same canaliculi without discharge. The same result was observed with upper canaliculi of the left eye and patency was observed at lacrimal irrigation of the right eye.

Dacryoscintigraphy was requested using Tc99m with result of complete obstruction at the level of left canaliculus or lacrimal sac, there is no evidence of obstruction in the lacrimal drainage of the right eye 30 minutes and 1 hour post instillation of Tc 99m (Picture 1 and 2). Treatment option for this patient is to do conjunctivo-dacryocystorhinostomy with Lester Jones, tube implantation of the left eye under local anesthesia and intravenous sedation.



Picture 1. Dacryoscintigraphy 30 minutes delay



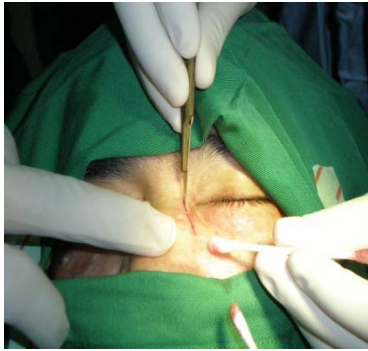Picture 2. Dacryoscintigraphy 1 hour delay

### Surgical Technique

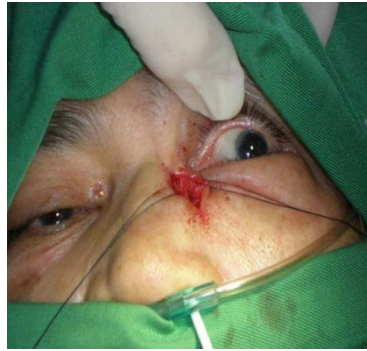After intravenous sedation was given, a mixture of lidocaine 2% with epinephrine 1:1000 was injected to anesthetize supra et infra trochlear nerve, infraorbital nerve and infiltrative along the previous skin incision. Skin incision was made at

the same site using blade 15 (Picture 3). Traction skin suture using 5-0 silk was done to expose the area. Blunt dissection was done with Steven's scissors up to the osteotomy site (Picture 4). A cotton applicator soaked with lidocaine was inserted through the left nostrill to aid the finding

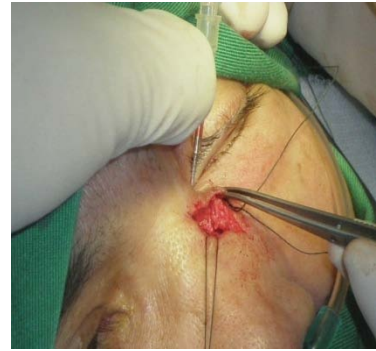of previous osteotomy and a fibrotic flap on osteotomy site was removed using a blade 11.



Picture 3. Skin incision created



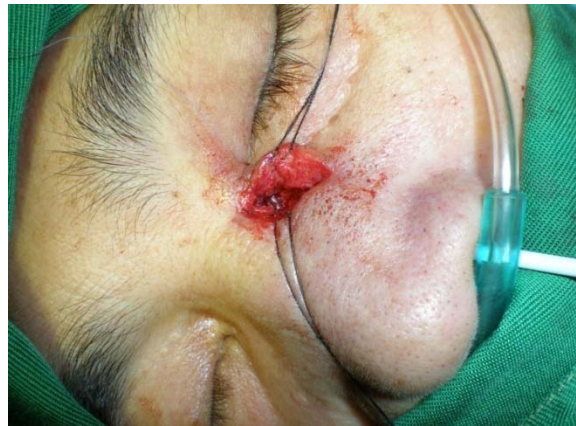Picture 4. Osteotomy site exposed



Picture 5. Tunnel made inferomedially

Measurement of the distance from the lacrimal caruncula to the osteotomy site was done which revealed 13 mm. This measurement was to determine the length of the tube to be implanted. A small incision was done at lacrimal caruncula using a blade 11 then a tunnel was made using a gauge

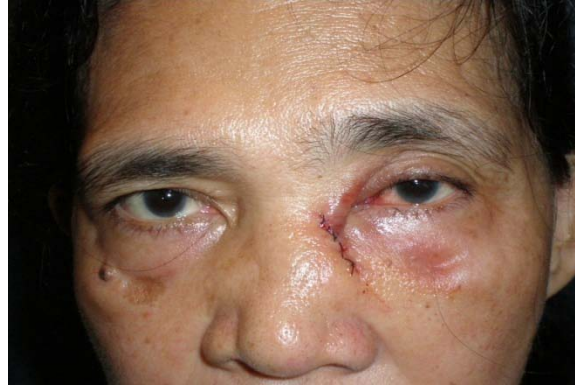19 needle inferomedially towards the osteotomy, and dilated using gold dilators (Picture 5). The 13-mm standard pyrex tube then implanted (Picture 6) and fixated at the caruncula using prolene 8-0 which will be removed after 4-6 weeks.



Picture 6. Jones tube implanted

Patency flow was evaluated by irrigating normal saline to the lower fornix, which in this case the patient was able to feel the water flowing to the throat. The wound then closed per layer using vicryl 6-0, and the skin was closed using interrupted 6-0 silk suture. Final patency evaluation was done and antibiotic-steroid (tobramycin + dexamethasone) eye ointment applied thinly on the suture line, and pressure

patch applied. There was no nasal pack used. Patient was given antibiotic-steroid eye drop (tobramycin-dexamethasone) 4 times a day for 2 weeks, Cloxacillin 500mg/tablet 4 times daily for 7 days and Mefenamic Acid 500 mg/tablet 3 times a day for pain. Follow up was done on first day post-op (Picture 7), first week, second week, and first month post surgery. Skin sutures were removed on the first week follow up.



Picture 7. One day post operatively with no epiphora, OS

Patient was advised to sniff and blow lightly through the nose during the first few weeks. If patients anticipate coughing, sneezing or must blow their nose, they should close their eyelids tightly and place a finger over the tube at the medial canthus (over the end of the tube) to prevent dislocation. The patient should be warned to avoid straining or vigorous exercise for 10-14 days post operative to decrease edema and the possibility of nasal bleeding. During follow up, irrigation with saline via an irrigating syringe or regular syringe attached to a piece of tubing was done to prevent mucus accumulation.<sup>6,7</sup> Patency of flow post operative was evaluated by demonstrating aspiration of fluorescein dye under the slitlamp. If the tube was dislocated or expelled, the patient was advised to seek consultation immediately. The tube was inspected every month for 6 months and at the time of examination patient does not experience any epiphora.

### Discussion

Conjunctivo-dacryocystorhinostomy (CDCR) is the standard treatment for proximal canalicular obstruction, in case of any unsuccessful surgery after dacryocystorhinostomy (DCR) with canalicular intubation, functional epiphora, trauma, lacrimal pump failure in cases of facial palsy, centurion syndrome, etc. Canalicular (proximal) obstruction can result from trauma, radiotherapy, Herpes simplex canaliculitis, congenital punctal/ canalicular agenesis, failed canalicular surgery, drugs e.g. 5-Fluorouracil, Stevens-Johnson syndrome. CDCR creates a drainage channel by connecting a tube through the

conjunctival space and the nasal space, bypassing the canaliculi and the lacrimal sac.<sup>1-5</sup>

Pre-operative information regarding possible complications post Lester Jones tube, implantation should be discussed with the patient such as the possibility of tube extrusion, malposition, development of keloid, granuloma, epistaxis, displacement of tube to the nasal septum and infection<sup>5,6,7</sup>. There are reports of rare complications regarding Lester Jones, tube implantation such as diplopia and restrictive strabismus due to conjunctival scarring, mycomicosis infection inside the tube, pseudodacryocystitis after Lester Jones, tube implant on children has been reported.<sup>8</sup>

The surgery can be done in local anesthesia unless in children or very anxious adults. In children patients, a longer Lester Jones tube will generally be required for children as they grow older and the distance from the medial canthus to the nasal cavity lengthens. Because co-operation and good care of the recipient is required to look after Jones' tubes, the procedure is best avoided in children under teenage or in the mentally retarded.

Some of the operative procedure it self must be taken into consideration such as meticulous hemostasis procedure is needed for nasal packing. If nasal packing needed, it should not be too high that it might obstruct the distal end of the tube. In case of exudate present, irrigation with antibiotic solution during surgery is mandatory and followed by parenteral antibiotics post operatively. Malposition of the tubes is one of

the most common complications encountered and placing the tube at a 45° angle several millimetres away from the nasal septum and anchoring it to the skin edge with a suture attached to the medial canthal flange will aid tremendously in preventing this complication.<sup>5,6,7,9</sup> Any difficulty in inserting the tube, the small end of the small metal/gold dilator should be inserted, followed by the larger end, then the small end of the larger dilator. This is followed by inserting the tube which is threaded, collar first, over a #1 Bowman Probe or a gauge 19. If any difficulty still encountered with the insertion, the larger end of the large dilator is inserted after which the pyrex tube will pass in easily. In case the passage has been contracted too much so it is too small for inserting the dilators, Bowman Probes may be inserted, followed by the curved Ziegler Punctum Dilator until the regular dilators can enter. If these procedure also failed, Zyllocaine 1% should be injected above and below the passage way followed by the insertion of a small Bowman Probe, so a canaliculus knife or even a sharp guide needle and Graefe Knife can be inserted.

Post operatively, the tube should be inspected routinely every 6-8 months, even though many patients can maintain clean tubes for years.<sup>5,6,7</sup> To remove the tube, a topical Proparacaine Hydrochloride (or similar) should be applied over the eye, before removing the tube from the CDCR ostium using the end of a lacrimal needle or with fingernail. At inspections, the bore of the bypass tube should be cleared of accumulated mucus using a plastic bristle and forceful irrigation with saline. Use a probe, smaller than the internal diameter of the tube, often necessary to clear debris, mucus etc. from the lumen. Inspiratory or expiratory effort with resistance can aid in clearing the tube and if the outer surface is not cleaned, a fibrous sheath tends to form, and causes recurrent infections. This cleaning must be done periodically, to prevent hard clodging around the tube and prevents proper drainage with excessive mucus accumulation, local irritation, etc. An alcohol solution would be able to remove the material and followed by replacing

the same tube which already cleaned and sterilized. Granulation tissue may also occur at either end of the tube and can usually be removed quite easily with toothed forceps and this problem occurs more often at the conjunctival end of the tube. It may also be helpful to apply carefully 0.5% silver nitrate sticks to aid in a cauterization procedure to prevent recurrences. Changing the diameter of the conjunctival flange, length and/or position of the tube may be necessary to aid in preventing recurrence of redundant mucosa or granulation tissue. Redundancy of the mucosa may accumulate at either end of the tube and should be carefully excised and cauterised if necessary. The flaccid conjunctiva tissue tends more easily to this problem than the more rigid nasal mucosa.

Lester Jones Tube is one of type of implants. It is made of pyrex glass which is an inert material, and introduced by Jones in 1962. The traditional Lester Jones tube has an external diameter of 3mm and has internal diameter of 0.8mm and angled tip of 30 degrees which will naturally suck up water through capillary force and does not produce bubbles (Picture 8). It was produced in different lengths and collar sizes, but this tube faces problems when implanted in patients with septum nasal deviations, turbinate abnormality, or hypertrophy. Then Chung, Kim and Sohn attached a #4 French rubber tip on the part distal of the Jones tube so the end of the tube reside inside the nasal cavity regardless of the anatomy variation of the nasal septum or the middle turbinate. India produces Aurotube which made of PMMA and thus cheaper.<sup>1,2,5</sup>

A Frosted Jones pyrex tube (Picture 9) introduced by Dailey and Tower which they claim to reduce post operative extrusion due to the better retention of the frosted outer surface pyrex tube with the tunnel compared to the smooth traditional pyrex tube. Chen Zhuo introduced Murube silicone tube (Picture 10), which is longer, more flexible and does not need to perforate the bone. This Murube silicone tube is injected using a trocar through vestibulum nasi, through the muscle underneath the skin above ala nasi then directly to the inferior part of medial canthus.<sup>1,2,5</sup> Devoto et al

used minimally invasive technique in implanting Lester Jones tube which is direct “poke through” from the conjunctiva to the middle meatus using a

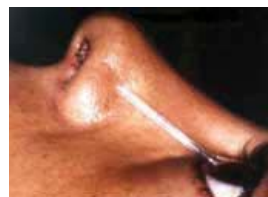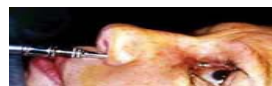14 gauge angiocatheter and then tube is inserted under direct endoscopic visualization.<sup>10</sup>



Picture8. Standard Lester Jones tube



Picture 9. Frosted Jones pyrex tube



Picture 10. Murube silicone tube

Locally in Philippines, the author cannot find any recent papers regarding Lester Jones tube implantation probably due to the scarcity of the availability of the tube it self. We look forward for more evidence locally with the experience of implanting Lester Jones Tube. We also recognize the short term of follow up of this patient and look forward to future maintenance of the surgical success.

### Conclusion

Epiphora is one of the causes of disabling factor for a person in a developing country because it can cause inability to read, drive, as result of over lacrimation and also the patient emotional well being. Regardless of reports found in the U.S and other developed country, conjunctivo-dacrycystorhinostomy with tube implantation is still uncommon in Philippines. Another reason might be the unavailability of the implant itself and this is the first CDCR with

Lester Jones tube implantation procedure done in Fatima Medical Center, as CDCR is the treatment of choice for complete nasolacrimal duct obstruction in the level of canaliculi and repeated failure in DCR causing epiphora.

As eye physicians, we should take attention not to do erroneus lacrimal apparatus irrigation using improper canula or a cut end needle which might produce fibrosis at the irrigation using improper canula or a cut end needle which might produce fibrosis at the canalicula thus causing upper level lacrimal duct obstruction.

### References

1. Lim C, Martin P, Bengner R, et al. Lacrimal canalicular bypass surgery with the Lester Jones tube. *AM J Ophthalmol* 2004; 137:101-8.
2. Welham RA, Guthoff R. The Lester Jones tube: a 15 year follow-up. *Graefes Arch Clin Exp Ophthalmol* 1985; 223:106-8.

3. McLean CJ, Rose GE : Posttherpetic lacrimal obstruction. *Ophthalmology* 2000;107:496-9.
4. Liu D. Conjunctival Incision for primary conjunctivodacryocystorhinostomy with Jones tube. *Am J Ophthalmol* 2000; 129:244-5.
5. Zilelioglu G. Gunduz K. Conjunctivodacryocystorhinostomy with Jones tube : a 10-year study. *Doc Ophthalmol* 1996/1997; 92:97-105.
6. Roger AD, Robert NT: Frosted Jones Pyrex tubes. *Ophthalmic Plastic and Reconstructive Surgery* 2005; 185-7.
7. Sekhar GC, Dortzbach RK, et al. Problems associated withconjunctivodacryocystorhinostomy. *Am J Ophthalmol* 1991; 112: 502-6.
8. Ashenhurst et al. Restrictive Strabismus following Jones tube insertion: a case series of 8 patients. *Can J Ophthalmol* 2007; 42: 613-6.
9. Bartley GB, Gustafson RO. Complications of malpositioned Jones tubes. *Am J Ophthalmol* 1990 ; 109(1) :66-9.
10. Trotter WL, Meyer DR. Endoscopic conjunctivodacryocystorhinostomy with Jones tube placement. *Ophthalmology* 2000; 107: 1206-9.



